

Note for Jane Doe on 2/23/05 - Chart 5407

Chief Complaint: This 31 year old female presents today with abdominal pain.

Duration: Condition has existed for one month.

Modifying Factors: Patient indicates lying down improves condition and standing worsens condition.

Severity: The severity has worsened over the past 2 weeks.

LMP: 4-05-2002.

Allergies: Patient admits allergies to penicillin.

Medication History: None.

Past Medical History: Past medical history is unremarkable.

Past Surgical History: Patient admits past surgical history of (+) cholecystectomy in 1998.

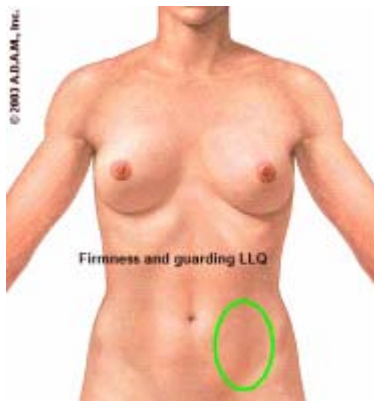
Social History: Patient denies alcohol use. Patient denies illegal drug use. Patient denies STD history. Patient denies tobacco use.

Family History: Patient admits a family history of cancer of breast associated with mother.

Review of Systems: Cardiovascular: (-) cardiovascular problems or chest symptoms

Constitutional Symptoms: (-) constitutional symptoms such as fever, headache, nausea, dizziness

Genitourinary: (-) GU symptoms



Physical Exam: BP Standing: 118/72 Resp: 18 HR: 68 Height: 5 ft. 7 in. Weight: 134 lbs. Patient is a 31 year old female who appears pleasant, in no apparent distress, her given age, well developed, well nourished and with good attention to hygiene and body habitus.

Eyes: Conjunctiva and lids reveal no signs or symptoms of infection. Pupil exam reveals round and reactive pupils without afferent pupillary defect. Optic discs with normal color, contour and cupping bilaterally. Retinas are flat with normal vasculature out to the far periphery with no peripheral holes, breaks or tears observed.

ENT: Gross hearing test reveals normal hearing. Inspection of bilateral ears reveals no masses, swelling, redness or drainage. Otoscopic examination reveals no abnormalities of external auditory canals and tympanic membranes. Inspection of nose reveals no abnormalities. Inspection of nasal mucosa, septum and turbinates reveals no abnormalities. Inspection of lips, teeth, gums, and palate reveals healthy teeth, healthy gums, no gingival hypertrophy, no pyorrhea and no abnormalities. Examination of oropharynx reveals no abnormalities.

Neck: Neck exam reveals no abnormalities. Thyroid examination reveals no abnormalities.

Lymphatic: No neck, supraclavicular, or axillary lymphadenopathy noted.

Respiratory: Assessment of respiratory effort reveals even respirations without use of accessory muscles and no intercostal retractions noted. Chest percussion reveals resonance. Chest palpation reveals no abnormal tactile fremitus. Auscultation of lungs reveal clear lung fields and no rubs noted.

Cardiovascular: The apical impulse on heart palpation is located in the left fifth intercostal space in the midclavicular line and no thrill noted. Heart auscultation reveals normal S1 and S2 and no murmurs, gallop, rubs or clicks. Examination of peripheral vascular system reveals full to palpation, varicosities absent, extremities warm to touch, no edema and no abnormalities.

Abdomen: Left lower quadrant of abdomen shows firmness and guarding. Examination for a hernia is negative. Palpation of liver reveals no abnormalities with respect to size, tenderness or masses. Palpation of spleen reveals no abnormalities with respect to size, tenderness or masses.

Genitourinary: Examination of vaginal vault reveals no abnormalities.

Musculoskeletal: Gait and station examination reveals midposition without abnormalities.

Extremities: Nails of fingers and toes do not demonstrate pitting or any other changes.

Skin: Inspection of skin outside of affected area reveals no abnormalities. Palpation of skin shows no abnormalities.

Neurological/Psychiatric: Testing of cranial nerves reveals no deficits. Deep tendon reflexes normal. Touch, pin, vibratory and proprioception sensations are normal. Patient judgment and insight is good. Oriented to person, place and time. Mood and affect normal and appropriate to situation.

Impression: Abdominal pain, lower left quadrant.

Plan: Diagnostic & Lab Orders: Ordered CT scan of the abdomen with contrast. Return to clinic in 1 week(s).

Patient Instructions:

Patient gives verbal and written consent for release of medical records.

Prescriptions:

Tylenol with Codeine Dosage: 300 mg-60 mg tablet Sig: TID Dispense: 24 Refills: 0 Allow Generic: Yes

_____ A. General Practitioner, MD

2/23/05

Marcus Welby, MD
1025 Ashworth Road, Suite 222
West Des Moines, IA 50265

Dear Dr. Welby:

Jane Doe was seen in my office in consultation as requested by you as a new patient for evaluation and care. The following is a summary of my findings and recommendations:

Impression: Abdominal pain, lower left quadrant.

Plan: Diagnostic & Lab Orders: Ordered CT scan of the abdomen with contrast. Return to clinic in 1 week(s).

Patient Instructions:

Patient gives verbal and written consent for release of medical records.

Prescriptions:

Tylenol with Codeine Dosage: 300 mg-60 mg tablet Sig: TID Dispense: 24 Refills: 0 Allow Generic: Yes

If I may be of any further assistance in the care of your patient, please let me know. Thank you for providing me the opportunity to participate in the care of your patients.

Sincerely,

Dr. Primary Care, MD

Medical Clinic

1025 Ashworth Road, Suite 222
West Des Moines IA 50265

PRESCRIBER: Dr. Primary Care, M.D.
TELEPHONE: (515)327-8850
DEA: 123456789

PATIENT: Jane Doe
ADDRESS: 1025 Ashworth Road
West Des Moines, IA 50265

TELEPHONE: 515-327-8850
DOB: 05/16/1973
DATE: 2/23/2005

R_x

Tylenol with Codeine, 300 mg-60 mg tablet

Disp: 24

Sig: TID

Refills: 0

DISPENSE AS WRITTEN
X GENERIC SUBSTITUTION PERMITTED

SIGNATURE OF PRESCRIBER

Patient Instructions for Jane Doe on 2/23/05

APPENDICITIS

What is it?

The vermiform appendix is a small, blind pouch leading off of the part of the intestine known as the cecum. It has no apparent function. Sometimes this pouch becomes inflamed and infected which is known as appendicitis. The causes are not known. The incidence of appendicitis is fairly common, about 1 in 500 people every year of any age. Although it is rare with children under 2, it is more common in men. The condition is treatable, but if ignored, a ruptured appendix is fatal. Other complications include abscess formation and peritonitis.

Signs and symptoms:

- * Localized abdominal pain extending from navel to lower right abdomen. Movement or respiratory efforts cause the pain to worsen.
- * Nausea and vomiting.
- * Low grade fever.
- * Constipation.
- * Swelling of abdominal in advanced stages.
- * White blood cell count increased.
- * Many times the signs and symptoms are not typical, therefore, misdiagnosis is possible.

Treatment:

- * There is no real way to prevent appendicitis from happening, however, it is curable with surgery.
- * To diagnose appendicitis, the doctor may order blood studies, urinalysis, and rectal temperature readings every 2 hours.
- * Once the diagnosis is confirmed, an appendectomy is performed to remove the appendix. Surgery cannot be performed if an abscess is present; once the abscess is healed, surgery can be undergone.
- * Before surgery or if you suspect appendicitis, do not take laxatives, enemas, or pain relievers and do not eat and drink anything until appendicitis is ruled out. Pain medicine is given post-operatively. Rest until surgery is performed.
- * Antibiotics to control infections.
- * Stool softeners for constipation.
- * Liquid diet.
- * Resume normal activities slowly after surgery.

Please call us after surgery if you have a high fever (over 102 degrees), vomit, have worse abdominal pain, pass out or have blood in vomit or stool. Also let us know if you have a headache or become dizzy.

_____ A. General Practitioner, MD

MEDICAL RECORDS RELEASE

I, _____,

hereby authorize _____

to release copies of my medical records to West Des Moines Family Care.

Signed: _____

Witness: _____

Date: _____

Please send copies of the above mentioned patient's medical records to the following address:

West Des Moines Family Care
1025 Ashworth Road, Suite 222
West Des Moines, IA 50265

Thank you.

_____ A. General Practitioner, MD



Billing Statement - Wednesday, February 23, 2005

Provider: A. General Practitioner, MD
Patient: Jane Doe, Chart 5407
1025 Ashworth Road, Suite 222
West Des Moines, IA 50265

Diagnoses

1. 789.03 Abdominal Pain, Right Lower Quadrant

Treatments

1. 99214 Office or other outpatient visit - est. patient - 25 min.
Related Diagnoses: 789.04
Modifiers:
Units:

Referring Physician: Marcus Welby, MD
Date Last Seen: 1-11-2003